

# Corticosteroid-resistant immune-related adverse events: a systematic review

Eveline Daetwyler <sup>1</sup>, Till Wallrabenstein <sup>1,2</sup>, David König <sup>1</sup>,  
Laura C Cappelli,<sup>3</sup> Jarushka Naidoo,<sup>4</sup> Alfred Zippelius <sup>1,5</sup>, Heinz Läubli <sup>1,5</sup>

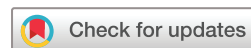**To cite:** Daetwyler E, Wallrabenstein T, König D, et al. Corticosteroid-resistant immune-related adverse events: a systematic review. *Journal for ImmunoTherapy of Cancer* 2024;**12**:e007409. doi:10.1136/jitc-2023-007409

► Additional supplemental material is published online only. To view, please visit the journal online (<http://dx.doi.org/10.1136/jitc-2023-007409>).

ED and TW contributed equally.

ED and TW are joint first authors.

Accepted 28 October 2023



© Author(s) (or their employer(s)) 2024. Re-use permitted under CC BY-NC. No commercial re-use. See rights and permissions. Published by BMJ.

<sup>1</sup>Division of Medical Oncology, University Hospital Basel, Basel, Switzerland

<sup>2</sup>Division of Hematology and Medical Oncology, University Medical Center Freiburg, Freiburg, Germany

<sup>3</sup>Division of Rheumatology, Johns Hopkins University School of Medicine, Baltimore, Maryland, USA

<sup>4</sup>Beaumont RCSI Cancer Centre, Dublin, Ireland

<sup>5</sup>Department of Biomedicine, University of Basel, Basel, Switzerland

## Correspondence to

Professor Heinz Läubli;  
[heinz.laebli@unibas.ch](mailto:heinz.laebli@unibas.ch)

## ABSTRACT

Immune checkpoint inhibitor (ICI) treatment has become an important therapeutic option for various cancer types. Although the treatment is effective, ICI can overstimulate the patient's immune system, leading to potentially severe immune-related adverse events (irAEs), including hepatitis, colitis, pneumonitis and myocarditis. The initial mainstay of treatments includes the administration of corticosteroids. There is little evidence how to treat steroid-resistant (sr) irAEs. It is mainly based on small case series or single case reports. This systematic review summarizes available evidence about sr-irAEs. We conducted a systematic literature search in PubMed. Additionally, we included European Society for Medical Oncology, Society for Immunotherapy of Cancer, National Comprehensive Cancer Network and American Society of Clinical Oncology Guidelines for irAEs in our assessment. The study population of all selected publications had to include patients with cancer who developed hepatitis, colitis, pneumonitis or myocarditis during or after an immunotherapy treatment and for whom corticosteroid therapy was not sufficient. Our literature search was not restricted to any specific cancer diagnosis. Case reports were also included. There is limited data regarding life-threatening sr-irAEs of colon/liver/lung/heart and the majority of publications are single case reports. Most publications investigated sr colitis (n=26), followed by hepatitis (n=21), pneumonitis (n=17) and myocarditis (n=15). There is most data for mycophenolate mofetil (MMF) to treat sr hepatitis and for infliximab, followed by vedolizumab, to treat sr colitis. Regarding sr pneumonitis there is most data for MMF and intravenous immunoglobulins (IVIg) while data regarding infliximab are conflicting. In sr myocarditis, most evidence is available for the use of abatacept or anti-thymocyte globulin (ATG) (both with or without MMF) or ruxolitinib with abatacept. This review highlights the need for prompt recognition and treatment of sr hepatitis, colitis, pneumonitis and myocarditis. Guideline recommendations for sr situations are not defined precisely. Based on our search, we recommend—as first line treatment—(1) MMF for sr hepatitis, (2) infliximab for sr colitis, followed by vedolizumab, (3) MMF and IVIg for sr pneumonitis and (4) abatacept or ATG (both with or without MMF) or ruxolitinib with abatacept for sr myocarditis. These additional immunosuppressive agents should be initiated promptly if there is no sufficient response to corticosteroids within 3 days.

## INTRODUCTION

Immune checkpoint inhibitor (ICI) treatment has become important for treating various cancer types. However, ICI can overstimulate the immune system leading to immunological side effects known as immune-related adverse

events (irAEs).<sup>1–3</sup> The occurrence of irAEs varies according to the immune checkpoint target (Programmed Death (PD)-1, Programmed Death-Ligand (PD-L)1, and Cytotoxic T-Lymphocyte-Associated Protein (CTLA)-4), the dosage regimen (dose of the CTLA-4 inhibitor), and if combined checkpoint blockage is used.<sup>1–4</sup> Generally, the risk and severity of irAEs are higher with CTLA-4 inhibitors than with PD-1/PD-L1 inhibitors,<sup>5</sup> and even higher with combined immune checkpoint blockage.<sup>6</sup>

Side effects from ICI treatment can be graded from mild to fatal severity.<sup>1–3 7</sup> Most often, irAEs are mild-to-moderate.<sup>1–3 7</sup> An analysis of 36 phase II and phase III trials, including more than 15,000 patients treated with various ICIs, has reported an incidence of any-grade irAEs in the range of 66–75% for PD-(L)1 inhibitors and 87% for the CTLA-4 inhibitor ipilimumab.<sup>8</sup> In this study, the cumulative incidence of grade 3 or 4 adverse events was estimated to be 14–20% for PD-1/PD-L1 inhibitors and 29% for the CTLA-4 inhibitor ipilimumab.<sup>8</sup> Rates of grade 3 or 4 adverse events have been reported as high as 59% for combined ICI treatment with ipilimumab and nivolumab.<sup>6</sup>

The initial treatment of irAEs often includes the administration of corticosteroids, depending on organ involvement and severity.<sup>1–3</sup> If there is no response or only an inadequate response to an initial corticosteroid treatment (within 1–3 days in the case of life-threatening irAEs, such as myocarditis, or within 7–14 days in the case of non-life-threatening irAEs, such as arthritis), the situation is classified as corticosteroid-resistant.<sup>1–3 9</sup> If there is a flaring during steroid-taper, the irAEs is steroid-dependent. A relapse is defined if the irAEs occur again after tapering or on re-exposure of the ICI treatment.<sup>10</sup> However, the definitions are not consistently applied. For the purpose of simplicity and due to the lack of a precise differentiation between the terms 'resistant' and 'refractory', we will use "resistant" in our

Protected by copyright. Including for uses related to text and data mining, AI training, and similar technologies.

J Immunother Cancer: first published as 10.1136/jitc-2023-007409 on 17 January 2024. Downloaded from <http://jitc.bmj.com/> on May 19, 2025 at Department GEZ-LTA ErasmusHogeschool.

review. These circumstances alone justify the great need for consulting experts in these situations.

The incidence of immune-related adverse events resistant to steroids (sr-irAEs) is unknown. It is presumed that the incidence depends on various factors, including the type and severity of adverse events as well as the treatment and disease setting. An exact assessment of the occurrence of sr-irAEs is further complicated by the current lack of a uniform definition.

Rapid and proper treatment escalation is crucial in cases of sr-irAEs, because the consequences of ineffective therapy are fatalities and chronic morbidity. However, the treatment recommendations for sr-irAEs are not defined precisely. They are often based on case reports and case series. This review aims to close this gap and to systematically search for evidence of treatment recommendations for sr-irAEs.

## METHODS

We conducted a systematic literature search in PubMed (search algorithms: see online supplemental appendix table A). Case reports were included due to the limited number of available studies. We additionally screened the European Society for Medical Oncology (ESMO), Society for Immunotherapy of Cancer (SITC), American Society of Clinical Oncology (ASCO) and National Comprehensive Cancer Network (NCCN) Guidelines and added studies, which were not covered by the systematic search. The population of each study had to consist of patients exposed to ICI-treatment who developed irAEs. These irAEs had to be treated initially with corticosteroids and a steroid-resistance had to be documented and/or additional immunosuppressive treatment had to be used. We have decided to limit our search to the corticosteroid-resistant setting of the four most clinically important and life-threatening organ sites affected by irAEs: liver, colon, lung and heart. Our literature search was not restricted to specific types of underlying cancer.

## MANAGEMENT OF STEROID-RESISTANT SITUATIONS BY ORGAN SITE (LIVER/COLON/LUNG/HEART)

### Hepatitis

#### Clinical presentation and epidemiology

Immune-related hepatitis is defined as at least a threefold increase of liver enzymes.<sup>1–3 11</sup> It typically manifests during routine blood monitoring with elevated levels of alanine aminotransferase and aspartate aminotransferase with or without elevated bilirubin.<sup>12</sup> Most patients are asymptomatic or present with only mild and non-specific symptoms such as fatigue or fever. The interval between start of ICI-treatment and the onset of liver toxicity varies considerably, depending also on the kind of applied checkpoint inhibitor(s).<sup>12–14</sup>

Immune-related liver injury occurs in approximately 2–6% of patients treated with PD-(L) 1-inhibitors, in 2–4% of patients treated with CTLA-4 inhibitors and in 29% of

patients (17% grade of toxicity G3–4) with combined CTLA-4/PD-1-inhibitor treatment.<sup>6 13 15–18</sup> The incidence of CTLA-4 inhibitor-related hepatitis is dose-dependent.<sup>19</sup> In a large retrospective real-world cohort of patients treated with ICIs, hepatitis occurred in approximately 5% of patients.<sup>20</sup> The median time to onset of hepatitis ranges between 3 and 9 weeks, with earlier onsets described in patients treated with combined CTLA-4/PD-1 inhibition.<sup>14</sup>

The incidence of steroid-resistant immune-related hepatitis is unknown, however retrospective reports about patients with immune-related (ir)-hepatitis requiring additional immunosuppression are in the range of 23–48%.<sup>20 21</sup> It is defined as either persistently elevated liver enzymes after 3–10 days of steroid treatment or recurrent increase of liver enzymes under steroid treatment.<sup>1–3 11</sup> Most cases of resistant immune-related hepatitis involve the setting of failure to primary corticosteroid treatment. Fewer cases refer to recurrence of elevated liver enzymes after initial resolve under steroid treatment. Reported cases/case series do not indicate a specific initial clinical presentation in these patients.

### Management

#### Consensus guidelines

International Guidelines (ESMO, ASCO, SITC, NCCN) as well as organ specific guidelines (American Gastroenterological Association (AGA)) agree on strict monitoring of liver enzymes and additional diagnostics (exclusion of toxic, viral or autoimmune hepatitis by patient history and serological testing, exclusion of hepatic disease progression by imaging) as basic diagnostic workup of ICI-related hepatitis.<sup>1–3 11</sup> Due to the paucity of evidence regarding steroid-resistant hepatitis, guideline recommendations for additional diagnostic and therapeutic measures are vague. Most guidelines agree in recommending a consultation with an hepatologist and to consider liver biopsy as additional diagnostic steps in case of steroid-resistance. Regarding additional immunosuppressive treatment options, all guidelines recommend mycophenolate mofetil (MMF) for which most retrospective evidence is available. Also, all guidelines advise against infliximab due to its hepatotoxic potential and risk for infectious complications due to immunosuppression (table 1).

#### Literature review

We have performed a structured literature search and have gathered data about treatment of steroid-resistant immune-related hepatitis (see online supplemental appendix table 5). A total of 22 publications have been identified, most of which are single case reports (n=13) or small case series of three or less patients with steroid-resistant hepatitis.<sup>12 16 20 22–39</sup> The largest available systematic case series by Cheung *et al* counts nine patients with steroid-resistant ICI-related hepatitis and has reported a faster normalization of liver parameters with additional immunosuppressive agents.<sup>20</sup> Another important observation in this series was that a higher dose of prednisone

**Table 1** Diagnostic and therapeutic recommendations for steroid-resistant hepatitis

	Guidelines			
	ESMO (2022) <sup>1</sup>	ASCO (2021) <sup>3</sup>	SITC (2021) <sup>2</sup>	NCCN (2023) <sup>40</sup>
Diagnostic procedures				
Repetition of initial workup	✓			✓
Rule out cytomegalovirus infection			✓	✓
Consultation with a hepatologist	✓	✓	✓	✓
Liver biopsy	✓	✓	✓	✓
Referral to tertiary center		✓		
Treatment options				
(1) First choice of additional immunosuppressive treatment.				
(2) Other options of immunosuppressive treatment.				
(*) No treatment sequence mentioned.				
Increase of steroid dose to 1–2 mg/kg/day in grade II	✓(*)			
Change to intravenous administration of steroid treatment	✓(*)			
Mycophenolate mofetil (peroral)	✓(*)	✓(*)	✓(*)	✓(1)
Tocilizumab (intravenous)	✓(*)			
Azathioprine (peroral)	✓(*)	✓(*)		✓(2)
Tacrolimus (peroral)	✓(*)		✓(2)	✓(2)
Anti-thymocyte globulin (intravenous)	✓(*)		✓(2)	✓(2)
Ciclosporin (peroral)	✓(*)			✓(2)
Do not use infliximab	✓(x)	✓	✓	✓

ASCO, American Society of Clinical Oncology; ESMO, European Society for Medical Oncology; NCCN, National Comprehensive Cancer Network; SITC, Society for Immunotherapy of Cancer.

(1 mg/kg daily) was not more efficient compared with a lower dose (50–60 mg daily), yet more likely to cause steroid-associated side effects.<sup>20</sup> Liver biopsy was mentioned in 12 of 22 reports.

Additional immunosuppressive treatment after failure of corticosteroid treatment was most frequently based on MMF in 18 of 22 publications.<sup>16 20–23 25 26 28–33 35–39</sup> Additional treatments with combined MMF plus either ursodeoxycholic acid, tacrolimus or infliximab were reported each in one publication.<sup>20 22 23</sup> Other reported additional treatments were ciclosporin (n=1),<sup>12</sup> azathioprine (n=1),<sup>24</sup> 6-mercaptopurine (n=1).<sup>25</sup> Use of infliximab in steroid-resistant immune-related hepatitis is not recommended by relevant guidelines because it has been associated with potentially severe treatment-related hepatotoxicity in patients with hepatitis.<sup>1–3 40</sup> Severe and fatal cases of hepatic injury from infliximab when used for sr-irAE other than hepatitis have also been reported.<sup>26 41</sup> Nevertheless, the use of infliximab for steroid-resistant hepatitis was reported in three cases, one in combination with MMF.<sup>20 27</sup>

Reported treatment options after failure of MMF were ATG (n=3)<sup>28 30 32</sup> and tacrolimus (n=1).<sup>22</sup> Across all identified case reports/case series, steroid-resistant hepatitis resolved with additional immunosuppression in 94% of all reported patient cases (see online supplemental

appendix table 5). Only one case of successful ICI rechallenge was reported after steroid-resistant hepatitis, successfully treated with MMF.<sup>26</sup>

The current treatment rationale for immune-related hepatitis is largely based on historic experiences in treating autoimmune hepatitis (AIH) and other autoimmune diseases with known immunosuppressive agents. More recently it has been shown that immune-related hepatitis is less related to AIH immunologically but rather to hepatic graft versus host disease (GVHD), which is characterized by lobular inflammation with presence of CD8+T cells and impaired activation of regulatory T cells.<sup>42</sup> Novel immune-modulatory treatment options such as extracorporeal photopheresis (ECP) and/or ruxolitinib that are already in use in the context of steroid-refractory acute GVHD could therefore be promising new treatment options.<sup>43–45</sup> ECP is currently investigated in a clinical trial (NCT05414552) (<https://clinicaltrials.gov/study/NCT05414552>, accessed on September 29, 2023).

#### Summary and recommendations

The incidence of steroid-resistant immune-related hepatitis is unknown and there is limited evidence regarding diagnostics and treatment. All guidelines agree that an hepatologist experienced in the matter should be consulted and a liver biopsy should be considered. If not



done in the initial workup, viral infections, AIH, hemochromatosis, hepatic disease progression and toxicity from other factors than ICI should be excluded. Evidence regarding treatment options is available only in the form of case reports and small case series. There is much evidence for MMF, which has been reported as a successful treatment of steroid-resistant ICI-related hepatitis in most published case reports. Other treatment options include ATG, azathioprine, ciclosporin and tacrolimus. Infliximab should be avoided due to potential infectious complications and hepatotoxicity. In addition, we recommend that treatment decisions as well as tapering of steroids after successful initiation of additional immunosuppression be discussed with an immune-oncologist as well as an organ expert who is experienced with managing irAEs.

## Colitis

### Clinical presentation and epidemiology

Immune-related colitis is one of the most common side effects of ICI treatment.<sup>46 47</sup> Its diagnosis requires either clinical, radiologic, or endoscopic evidence of enterocolonic inflammation. Immune-related colitis manifests as diarrhea, which is often accompanied by abdominal pain, hematochezia, weight loss, fever and vomiting.<sup>48 49</sup> Importantly, immune-related colitis increases the risk of complications, such as ileus, perforation or even death.<sup>48 49</sup>

Immune-related colitis occurs most frequently in patients treated by combined immunotherapies with CTLA-4 inhibitor and PD-1 inhibitor (11.8% of all patients), followed by single-agent treatment with CTLA-4 inhibitor (11.6%) and PD-1 inhibitor (1.3%).<sup>50</sup> The incidence of colitis in patients treated with CTLA-4-inhibitors is dose-dependent.<sup>19</sup> The median interval from administration of the first dose of CTLA-4-inhibitor to onset of immune-related colitis has been reported to be approximately 1 month, and 2–3 months after administration of PD-(L)1-inhibitors.<sup>49 51 52</sup>

Patients with persistent colon inflammation revealed in the endoscopic examination and/or lack of clinical response to corticosteroids are considered resistant.<sup>49</sup> It is estimated that about one-third to two-thirds of all patients do not respond to first-line treatment of high-dose intravenous corticosteroids or suffer a relapse during the course of steroid tapering.<sup>11 48</sup> Colonic ulcerations, higher endoscopic scores, such as the often used Mayo Endoscopic Subscore,<sup>53 54</sup> and/or pancolitis are associated with a higher risk of steroid-resistant disease.<sup>53–56</sup>

## Management

### Consensus guidelines

Guidelines (ESMO, ASCO, SITC, NCCN, AGA) for immune-related colitis focus mainly on the initial management describing three strategies depending on the severity of immune-related colitis and the duration of symptoms: discontinuation of ICI-treatment, start of immunosuppressive corticosteroid-treatment and supportive measures such as hydration.<sup>1–3 40</sup> Unfortunately, failure

of these initial management strategies is common due to steroid-resistant situations.

In steroid-resistant colitis, guidelines suggest the following diagnostic management strategy: a complete initial workup with blood analysis and stool analysis to rule out infective disease and to measure calprotectin or lactoferrin and endoscopy with biopsies if not conducted in the initial management. Radiologic diagnosis is not the appropriate diagnostic method to detect immune-related colitis. However, it should be carried out if complications are suspected (eg, perforation, abscess). A gastroenterologist should be involved, also to evaluate re-endoscopy with biopsies (table 2).<sup>1–3 11 40</sup> One of the most frequently used endoscopic measurement scale is the Mayo Endoscopic Subscore, ranging from 0 (no inflammation) to 3 (colonic ulceration).<sup>57 58</sup>

All guidelines recommend the administration of infliximab or vedolizumab as first-line treatment.<sup>1–3 11 40</sup> Since there is currently no available data comparing infliximab to vedolizumab in the first-line treatment, the decision between these two agents should be based on clinical factors, such as expected duration of treatment, degree of severity, concurrent other irAEs, underlying malignancy, comorbidities and risk of infection.<sup>11 16</sup> Additional immunosuppressive agents to treat steroid-resistant colitis are: tofacitinib, ustekinumab, MMF, fecal microbiota transplantation and extracorporeal photopheresis.<sup>1–3 11 40</sup> Surgical options should be evaluated in patients with toxic megacolon, intra-abdominal abscesses or perforation<sup>1</sup> (table 2).

### Literature review

We identified in our literature search 27 publications about the management of steroid-resistant colitis, including 12 case reports<sup>59–70</sup> and 15 case series<sup>16 56 71–83</sup> (see online supplemental appendix table 6). Stool examination to rule out infectious disease with/without stool calprotectin or lactoferrin, blood laboratory tests and endoscopic examinations with/without biopsies were carried out according to almost all publications,<sup>56 59–75 77–84</sup> except for one publication in which no diagnostic approach was mentioned.<sup>16</sup> Additional abdominal imaging was recommended in three publications.<sup>64 67 83</sup>

After failure of initial high-dose corticosteroid treatment the following immunosuppressive agents were used: infliximab (n=10),<sup>16 56 59 63–65 71–74</sup> vedolizumab (n=2)<sup>60 75</sup> or a combination of these two agents (n=4).<sup>66 77 82 84</sup> For colitis resistant to infliximab and/or vedolizumab, the use of oral calcineurin inhibitors (tacrolimus, ciclosporin) (n=3),<sup>61 78 79</sup> rapamycin with tacrolimus (n=1),<sup>78</sup> ustekinumab (n=1),<sup>67 80</sup> tofacitinib (n=4),<sup>62 68 70 83</sup> stool transplantation (n=1)<sup>81</sup> and extracorporeal photopheresis (n=1)<sup>69</sup> have been described. Overall, most evidence of evidence exists for infliximab as first-line treatment in steroid-resistant colitis. The administration was successful in most cases, resulting in a complete clinical remission or in relevant clinical improvement of gastrointestinal symptoms after one to three infusions. Additionally, Abu-Sbeih

**Table 2** Diagnostic and therapeutic recommendations for steroid-resistant colitis

	Guidelines			
	ESMO (2022) <sup>1</sup>	ASCO (2021) <sup>3</sup>	SITC (2021) <sup>2</sup>	NCCN (2023) <sup>40</sup>
<b>Diagnostic procedures</b>				
Blood analysis (eg, complete blood count, blood chemistry with electrolytes, renal and liver function, thyroid function test)	✓	✓	✓	✓
Stool analysis for enteropathogenes, <i>Clostridium difficile</i> toxin, cytomegalovirus (initial or in resistant situation)	✓	✓	✓	✓
Fecal lactoferrin, calprotectin	✓	✓	✓	✓
Abdominal X-ray, CT of the abdomen and/or pelvis (for detecting complications)	✓	✓	✓	✓
Sigmoidoscopy, colonoscopy	✓	✓	✓	✓
Consultation with a gastroenterologist	✓	✓	✓	✓
Repeat endoscopy	✓	✓	✓	✓
<b>Treatment options</b>				
(1) First choice of additional immunosuppressive treatment.				
(2) Other options of immunosuppressive treatment.				
Infliximab (intravenous)	✓(1)	✓(1)	✓(1)	✓(1)
Vedolizumab (intravenous)	✓(1)	✓(1)	✓(1)	✓(1)
Tofacitinib (peroral)	✓(2)	✓(2)		
Ustekinumab (intravenous)	✓(2)	✓(2)		
Mycophenolate mofetil (peroral)	✓(2)			
Fecal microbiota transplantation	✓(2)	✓(2)		✓(2)
Extracorporeal photopheresis	✓(2)			
Colectomy	✓(2)			
ASCO, American Society of Clinical Oncology; ESMO, European Society for Medical Oncology; NCCN, National Comprehensive Cancer Network; SITC, Society for Immunotherapy of Cancer.				

*et al* described how the early administration of infliximab and/or vedolizumab within less than 10 days, regardless of corticosteroid responsiveness, was essential for the improvement of the symptoms and that the recurrence rate of immune-related colitis was higher in infliximab monotherapy (26%) than in vedolizumab monotherapy (3%)<sup>84</sup> (see online supplemental appendix table 6). Additionally, there is some evidence available on the use of these agents (infliximab, vedolizumab) to manage immune-related colitis while resuming ICI-treatment.<sup>85 86</sup> However, this approach remains investigational, and we await further studies prior to using it routinely in clinical practise.

The current treatment rationale for immune-related colitis is mainly based on experiences in treating inflammatory bowel diseases (IBD).<sup>87</sup> It is well established that T cells and cytokines/interferons play an important role in immune-related colitis.<sup>74 87 88</sup> In steroid-refractory immune-related colitis, anti-Tumor Necrosis Factor (TNF)- $\alpha$  treatment with infliximab is often initiated, especially when the inflammation is severe (correlation TNF- $\alpha$  and inflammation), according to studies in

IBD.<sup>89 90</sup> In contrast to the unspecific action of infliximab, vedolizumab has a specific effect in the intestinal tract by blocking the  $\alpha 4\beta 7$ -integrin which is involved in homing of T cells to the intestinal tract.<sup>60 75 91 92</sup> In addition to modulating the immune system pathways, another approach for treating immune-related colitis is targeting the microbiome. Promising outcomes with stool transplantations in the context of recurrent *Clostridium difficile* infections<sup>93–97</sup> and IBD, especially in ulcerative colitis,<sup>98–101</sup> led to considerations of this approach in immune-related colitis.<sup>81</sup>

### Summary and recommendations

To conclude, in immune-related colitis prompt diagnostic procedures with mandatory endoscopic examination and the initiation of treatment are crucial. Overall, about half of the patients with moderate-to-severe colitis do not respond to corticosteroids.<sup>116</sup> According to the guidelines and based on our literature review infliximab is the most commonly used agent in steroid-resistant colitis, leading to satisfactory improvement for almost all patients, especially if introduced at an early stage. In addition, the

response is fast and shows efficacy in the presence of coexisting irAEs. However, about 11% of these patients are infliximab-refractory and require additional immunosuppressive agents.<sup>116</sup> In these situations, vedolizumab should be considered as a gut-specific immunosuppressive treatment. However, the onset of the effect of vedolizumab is slower and is therefore not recommended in severe colitis. However, these recommendations are based on a small number of eligible studies with small population sizes thus limiting the level of evidence. Therefore, a discussion at an immune-oncological board with experts (immune-oncologist and gastroenterologist experienced in managing irAEs) remains important.

## Pneumonitis

### Clinical presentation and epidemiology

ICI-related pneumonitis has no uniform definition and may refer to different clinical and radiological manifestations. In general, it is defined as inflammation of lung tissue. Patients usually present with one or more of the following symptoms: dyspnea, hypoxia, cough, chest pain, and/or fever.<sup>1-3 40</sup> Characteristic radiographic findings of pneumonitis have been summarized by Naidoo *et al.*<sup>10</sup> Pre-existing non-malignant lung disease, lung cancer, smoking, radiotherapy to the chest and concomitant treatment with pneumotoxic medication have been identified as risk factors of ICI-related pneumonitis<sup>10 102</sup> and these factors also pose a challenge for differentiating ICI-related pneumonitis from other causes of lung damage.

ICI-related pneumonitis is most frequent in patients treated with combined PD-(L)1 and CTLA-4-inhibition (10%).<sup>10</sup> It occurs in approximately 2.5–4% of patients receiving anti-PD-1, in 2% of patients receiving anti-PD-L1 and in 1% of patients receiving anti-CTLA-4 treatment.<sup>10 103 104</sup> A median time to onset of 2.5–2.8 months has been reported.<sup>10 14</sup> While ICI-related pneumonitis is a rare event, it is however frequently serious with up to one-third of patients presenting with events of grade 3 or higher and fatal outcome in up to 12% of patients.<sup>10 105</sup>

Higher grade pneumonitis often does not respond to corticosteroid treatment alone and requires additional immunosuppression. In a review of 64 patients who developed checkpoint-inhibitor induced pneumonitis, 6 patients (9.4%) had fatal pneumonitis and 1 patient (1.6%) had worsening pneumonitis despite prednisone treatment.<sup>105</sup> Another retrospective analysis of 43 patients with pneumonitis by Naidoo *et al* showed that nearly all cases of grade 1 and 2 pneumonitis resolved with corticosteroids, whereas grade 3 and 4 pneumonitis frequently mandated additional immunosuppressive agents.<sup>10</sup> Yet another report has found steroid-resistance in 12 of 65 patients (18.5%) with immune-related pneumonitis.<sup>106</sup> Grade 3 or higher pneumonitis as well as worsening pneumonitis, that is, resistant to steroid treatment and requires additional immunosuppression, have been associated with primary tumor site (especially lung cancer), current smoking, and with underlying lung disease.<sup>10 107</sup>

Recurrent pneumonitis following a first episode of immune-related pneumonitis is frequent (25% of patients), both spontaneously and in patients who had rechallenge to ICIs (recurrent pneumonitis in 25–43% of patients).<sup>10 108</sup> A minority of patients (14% of patients) with pneumonitis may develop chronic low grade pneumonitis, which persists despite ICI-discontinuation and may not resolve after 3 months of corticosteroids.<sup>3 109</sup>

## Management

### Consensus guidelines

Guidelines (ESMO, ASCO, SITC, NCCN) essentially agree on two recommendations concerning the management of grade 2 or higher immune-related pneumonitis: discontinuation of ICI-treatment and start of immunosuppressive (high-dose) corticosteroid-treatment.<sup>1-3 40</sup> There are no consistent recommendations regarding the diagnostic and therapeutic management of steroid-resistant pneumonitis. Guideline recommendations are summarized in table 3. There is consensus that in the case of higher-grade pneumonitis and/or steroid-resistance, differential diagnoses must be excluded (infection, embolism, effusion, tumor progression/carcinomatosis, or cardiac cause). If not done during the initial workup, diagnostic steps should therefore include high-resolution chest CT, bronchoalveolar lavage and consultation with a specialist.<sup>1-3 40</sup> Transbronchial lesion biopsy can be considered on an individual basis.<sup>3 40</sup>

According to all guidelines, failure of corticosteroid treatment is defined as lack of improvement within 48–72 hours and should prompt immediate treatment escalation.<sup>1-3 40</sup> Steroid-resistant grade 2 pneumonitis should be treated as grade 3 with high-dose intravenous corticosteroids.<sup>1 3 40</sup> Additional immunosuppressive treatment options include MMF, cyclophosphamide, intravenous immunoglobulins (IVIG) and infliximab.<sup>1-3 40</sup>

### Literature review

We have performed a structured literature search and have gathered data about treatment of steroid-resistant immune-related pneumonitis (see online supplemental table 7). Seventeen publications have been identified, nine of which are single-case reports.<sup>10 26 39 106 107 110-121</sup> Signs of efficacy to treat steroid-resistant immune-related pneumonitis have been reported for different immunosuppressive agents, including IVIG, MMF, cyclophosphamide, tocilizumab and infliximab.<sup>10 26 106 107 110</sup> However, there is no prospective or comparative data in this situation and there are no treatment recommendations favoring one agent over another. There is a small number of retrospective analyses of patients with pneumonitis that include patients with steroid-resistant pneumonitis.<sup>10 26 106 107 110 111</sup> Common to each of these reports is a high fatality rate of 67–100% for patients with steroid-resistant pneumonitis, regardless which additional suppressive line treatment was chosen.

Most evidence is available for infliximab, however with contradictory results. Several single case reports have

**Table 3** Diagnostic and therapeutic recommendations for steroid-resistant pneumonitis

	Guidelines			
	ESMO(2022) <sup>1</sup>	ASCO (2021) <sup>3</sup>	SITC(2021) <sup>2</sup>	NCCN(2023) <sup>40</sup>
Diagnostic procedures				
High resolution chest-CT, if not previously done	✓	✓	✓	✓
Bronchoalveolar lavage, if not previously done	✓	✓		✓
Refer to or consult with specialist	✓	✓		✓
Treatment options				
(1) First choice of additional immunosuppressive treatment.				
(2) Other options of immunosuppressive treatment.				
(*) No treatment sequence mentioned.				
Continue intravenous steroids	✓(x)	✓(x)		✓
Escalate after 48 hours if no improvement		✓(x)		✓
Immunoglobulin (intravenous)	✓(1)	✓(*)	✓(*)	✓(*)
Mycophenolate mofetil (peroral)	✓(2)	✓(*)	✓(*)	✓(*)
Cyclophosphamide (intravenous)	✓(2)	✓(*)	✓(*)	
Infliximab (intravenous)	✓(1)	✓(*)	✓(*)	✓(*)
Tocilizumab (intravenous)	✓(1)		✓(*)	
Consider upfront tocilizumab or infliximab in addition to steroid treatment in case of life-threatening symptoms	✓(x)			
ASCO, American Society of Clinical Oncology ; ESMO, European Society for Medical Oncology ; NCCN, National Comprehensive Cancer Network ; SITC, Society for Immunotherapy of Cancer.				

reported significant improvement of steroid-resistant ICI-related pneumonitis on infliximab administration, however such reports harbor selection bias as treatment failures tend to get reported less often. Only low success rates of infliximab in the range of 25–33% have been reported in the retrospective studies of Luo *et al.*,<sup>26</sup> Nishino *et al.*<sup>107</sup> and Beattie *et al.*,<sup>111</sup> whereas all treatment attempts with infliximab were negative in the retrospective studies by Naidoo *et al.* and Balaji *et al.*<sup>10, 106</sup> Due to these conflicting results, infliximab in the setting of steroid-resistant pneumonitis has more recently been called into question.<sup>106</sup>

IVIG has been suggested as alternative additional immunosuppressive treatment in steroid-resistant pneumonitis, based on one single case report<sup>112</sup> and one retrospective case series by Balaji *et al.* which has reported a successful improvement of pneumonitis in four of seven patients treated with IVIG.<sup>106</sup> Currently, a prospective trial is being conducted by Eastern Cooperative Oncology Group (ECOG) and the American College of Radiology Imaging Network (ACRIN) that compares infliximab versus IVIG as additional immunosuppression in steroid-resistant immune-related pneumonitis (NCT04438382) (<https://classic.clinicaltrials.gov/ct2/show/NCT04438382>, accessed on February 12, 2023).

Signs of efficacy for the use of tocilizumab in the treatment of immune-related pneumonitis comes from a single-center retrospective study including 34 patients (predominantly patients with lung cancer) with sr-irAEs, including 12 patients with pneumonitis.<sup>113</sup> Among all

patients, 79.4% demonstrated clinical improvement from tocilizumab treatment, and most patients required only a single or two doses.

Beattie *et al.* have reported durable improvement of steroid-resistant ICI-associated pneumonitis in five of six patients treated with MMF as additional immunosuppression.<sup>111</sup> Camard *et al.* have reported improvement and survival beyond 5 months in two of four patients treated with cyclophosphamide.<sup>110</sup>

The underlying pathomechanism of ICI-related pneumonitis is likely based on T-cell autotoxicity due to shared epitopes between tumor and lung.<sup>122</sup> Bronchoalveolar lavage (BAL) from patients with ICI-related pneumonitis has shown T-cell dominated lymphocytosis with upregulation of pro-inflammatory CD8/TNF- $\alpha$ /interferon- $\gamma$ -positive T cells, upregulation of CD8-positive T cells co-expressing checkpoint-inhibitors such as PD-1 and T-cell immunoglobulin and mucin-domain containing (TIM)-3 and downregulation of anti-inflammatory CD4/PD-1/CTLA4-positive regulatory T cells.<sup>123</sup> Suppression of T-cell mediated auto-immunity is likely the reason why immunosuppressive agents such as MMF and cyclophosphamide might alleviate ICI-related pneumonitis. Pro-inflammatory cytokines were also found to be elevated in BAL of patients with ICI-related pneumonitis, thus providing some rationale for cytokine-directed treatments such as infliximab or tocilizumab, however the main mechanism of inflammation appears to be cellular.<sup>124</sup> Apart from T-cellular mechanisms, also auto-immune antibodies seem to play a role in pneumonitis.<sup>125</sup>



The neutralization of such autoimmune antibodies might be the reason why IVIG have been found to improve ICI-related pneumonitis.

### Summary and recommendations

The incidence of immune-related pneumonitis is low, however resistance to steroid treatment may occur in 10–20% of patients and is associated with a high fatality rate. Steroid-resistant pneumonitis is associated with lung cancer, other underlying lung disease and smoking. No prospective data is available with regard to diagnostics and treatment of steroid-resistant pneumonitis. Most retrospective data is available for infliximab, however with conflicting and hardly encouraging results. Other options with less evidence but reports of higher success rates are IVIG, tocilizumab, MMF and cyclophosphamide. Wherever possible, these options should probably be explored before infliximab is applied. However, prospective evidence is necessary to answer this question. We generally recommend that treatment decisions as well as tapering of steroids after successful initiation of additional immunosuppression be discussed with immune-oncologists and pneumologists experienced with managing irAEs.

## Myocarditis

### Clinical presentation and epidemiology

Immune-related myocarditis is a rare side effect of ICI treatment, but is potentially life-threatening.<sup>126–128</sup> The prevalence of myocarditis is approximately 1.14%.<sup>126</sup> About half of the number of patients with ICI-related myocarditis experience a major adverse cardiac event, defined as occurrence of cardiovascular death, cardiogenic shock, cardiac arrest or hemodynamically significant complete heart block.<sup>126</sup> In a retrospective analysis, 50% of patients diagnosed with immune-related myocarditis died.<sup>127</sup>

Diagnosing ICI-related myocarditis requires either an endomyocardial biopsy or concordant findings from clinical, laboratory, electrocardiographic and imaging examinations.<sup>129–130</sup> The clinical presentation is highly variable, ranging from subclinical disease (ECG or laboratory phenomena with elevated cardiac biomarkers) to chest pain and major cardiac events.<sup>1–3 40 129 130</sup> It is often associated with concurrent myositis and a myasthenia gravis-like syndrome which often require additional immunosuppressive agents beyond corticosteroids.<sup>127 128</sup>

Fortunately, the overall occurrence of immune-related myocarditis remains rare. According to a pharmacological safety database it occurs more often in patients receiving combined anti-PD-1 and anti-CTLA-4 treatment than in patients receiving only an anti-PD-1 monotherapy (0.27% vs 0.06%).<sup>131</sup> The median interval from starting ICI treatment to onset of immune-related myocarditis has been described to be approximately 5 weeks.<sup>1</sup>

Patients with worsening symptoms, persistently elevated or increasing cardiac biomarkers, occurrence of cardiac arrhythmias and/or reduced ventricular ejection fraction despite high-dose corticosteroids are considered

resistant.<sup>1</sup> The percentage of patients with steroid resistance is still unknown.

## Management

### Consensus guidelines

Guidelines (ESMO, ASCO, SITC, NCCN, European Society of Cardiology) for immune-related myocarditis focus mainly on the initial management, recommending discontinuation of ICI-treatment, start of immunosuppressive high-dose corticosteroid-treatment and hospital admittance.<sup>1–3 132</sup> The initial diagnostic assessment should be completed in steroid-resistant myocarditis including a complete initial workup with blood analysis, ECG, echocardiography, cardiac MRI, ruling out vascular heart disease (catheterization or imaging) and evaluation of endomyocardial biopsy as well as the consultation of a cardiologist (table 4).<sup>1–3 129 130 132</sup>

After the diagnostics procedures, the guidelines recommend the following immunosuppressive agents for the treatment of steroid-resistant immune-related myocarditis: infliximab, MMF, ATG, abatacept, alemtuzumab, tocilizumab and immunoglobulins. Hereby, the administration of MMF, ATG, abatacept and alemtuzumab is recommended by all guidelines. But most evidence of efficacy for first line use in steroid-resistance is MMF. Infliximab is recommended by ASCO and NCCN Guidelines, whereas in the SITC and ESMO Guidelines its use is critically evaluated as a result of the study by Cautela *et al* who have shown an increased risk of cardiovascular death after the administration of infliximab (table 4).<sup>1–3 40 133</sup>

### Literature review

There is limited available evidence regarding the management of steroid-resistant myocarditis. We have identified 15 publications of which 13 publications<sup>134–146</sup> were case reports, 2 publications were smaller case series with 4 patients<sup>147</sup> and 16 patients<sup>148</sup> and one study included a study population of 30 patients treated with additional immunosuppressive agents<sup>149</sup> (see online supplemental appendix table 8). All the included publications suggested blood analysis, ECG and echocardiography as the first diagnostic approach.<sup>134–149</sup> Four publications recommended in addition conducting a cardiac MRI<sup>134 136 137 139 149</sup> or gallium-68 DOTATOC imaging<sup>146</sup> and eight publications the visualization of the coronary vessels by using imaging or percutaneous catheters.<sup>134 136 138 140–143 145 149</sup> Only in two publications was a cardiac biopsy carried out as a diagnostic procedure in all or at least some study patients.<sup>142 143 149</sup> Cardiac MRI or biopsy is recommended by Zhang *et al*.<sup>147</sup>

The initial management of ICI-related myocarditis included the administration of high-dose corticosteroids in all cases. The following additional immunosuppressive agents were investigated (alone or in combination): abatacept,<sup>134–136 140 149</sup> oral MMF,<sup>135 140 142 144</sup> ruxolitinib,<sup>149</sup> alemtuzumab,<sup>137</sup> infliximab,<sup>138 147 148</sup> IVIG,<sup>138 145 148</sup> plasmapheresis,<sup>139–141</sup> tacrolimus,<sup>139</sup> abatacept,<sup>140</sup> ATG,<sup>142–144</sup> tofacitinib<sup>145 148</sup> and tocilizumab.<sup>146</sup> All the above



**Table 4** Diagnostic and therapeutic recommendations for steroid-resistant myocarditis

	Guidelines			
	ESMO (2022) <sup>1</sup>	ASCO (2021) <sup>3</sup>	SITC (2021) <sup>2</sup>	NCCN (2023) <sup>40</sup>
<b>Diagnostic procedures</b>				
Blood analysis (troponin, creatine kinase/-MB, N-terminal pro-B-type natriuretic peptide/brain natriuretic peptide)	✓	✓	✓	✓
ECG	✓	✓	✓	✓
Echocardiography	✓	✓	✓	✓
Cardiac Imaging: Cardiac MRI, cardiac Ga-DOTATOC, FDG-PET-CT	✓	✓	✓	✓
Endomyocardial biopsy (endovascular)	✓	✓	✓	✓
Cardiac stress testing or heart catheterization	✓	✓		
Chest X-ray		✓		
Consultation with a cardiologist	✓	✓	✓	✓
<b>Treatment options</b>				
(1) First choice of additional immunosuppressive treatment. (2) Other options of immunosuppressive treatment. (*) No treatment sequence mentioned.				
Infliximab (intravenous)		✓(1)		✓(*)
Mycophenolate mofetil (peroral)	✓(1)	✓(1)	✓(*)	✓(*)
Anti-thymocyte globulin (intravenous)	✓(2)	✓(1)	✓(*)	✓(*)
Abatacept (intravenous)	✓(2)	✓(2)	✓(*)	✓(*)
Alemtuzumab (intravenous)	✓(2)	✓(2)	✓(*)	✓(*)
Tocilizumab (intravenous)	✓(1)			
Immunoglobulin (intravenous)				✓(*)
ASCO, American Society of Clinical Oncology ; creatine kinase-MB, heart specific isoenzyme of creatine kinase; ESMO, European Society for Medical Oncology ; FDG-PET, Fluorodeoxyglucose-Positron Emission Tomography; Ga-DOTATOC, Gallium-based ligand binding to somatostatin receptors; NCCN, National Comprehensive Cancer Network ; SITC, Society for Immunotherapy of Cancer.				

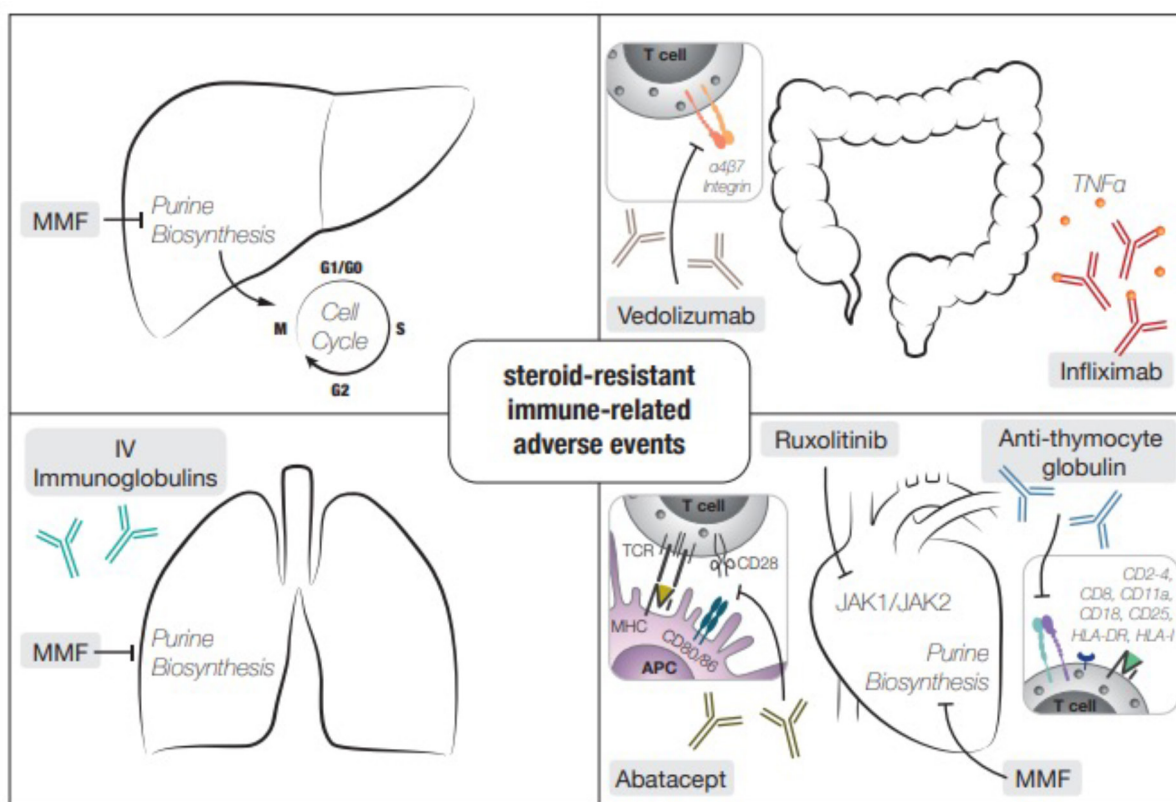
procedures led to a complete or partial resolution of the clinical symptoms, laboratory findings and echocardiography examinations, except for three studies using infliximab combined with IVIG,<sup>138</sup> infliximab alone<sup>148</sup> or ATG<sup>144</sup> (see online supplemental appendix table 8). In the largest study population, 30 patients were treated with a combination of ruxolitinib and abatacept. Hereby, the fatality rate due to myocarditis could be significantly reduced to 3.4% (control group: fatality rate of 60%) in the first observation interval.<sup>149</sup>

The detailed pathophysiological mechanisms of ICI-related myocarditis are still unclear. An infiltration of T cells into the myocardium seems to be an important condition for ICI-related myocarditis,<sup>131</sup> as observed in a monkey model.<sup>150</sup> To target T-cell activation and thus reducing infiltration, abatacept blocks T-cell interactions with antigen-presenting cells (CD86/CD28). Initially, abatacept was used in rheumatic diseases, and a trial of its effect on myocarditis in rheumatoid arthritis is currently underway (NCT03619876, <https://clinicaltrials.gov/study/NCT03619876>, accessed on September 29, 2023). ATG also targets the T-cell infiltration by causing a T-cell depletion, similar to patients with heart transplant.<sup>142</sup>

Other important pathways involved in ICI-related myocarditis are the JAK2 signaling pathways.<sup>149</sup> It was shown in mice and human that JAK2 signaling pathways are upregulated in ICI-related myocarditis, thus providing some rationale for JAK1/JAK2 inhibitors such as ruxolitinib<sup>149</sup> in this setting. Additionally, ruxolitinib may decrease the antigen presentation in the myocardium and block the proapoptotic functions of interferons.<sup>151 152</sup>

### Summary and recommendations

Although immune-related myocarditis is a rare irAE, it is crucial to identify and treat it promptly due to its potentially fatal outcome. Due to its high fatality rate, even an upfront combination treatment with immunosuppressive agents should be considered. Clear evidence with regard to treatment cannot be provided as all available publications are case reports of one patient or only small case series. Overall, most beneficial evidence is available for the use of abatacept or ATG (both with or without MMF) or ruxolitinib with abatacept in treating steroid-resistant myocarditis. There is no convincing evidence for the use of infliximab in this setting. We generally recommend that treatment decisions should be discussed with



**Figure 1** Overview of different activities of immunosuppressants used in the treatment of immune-related organ toxicities. Standard treatment of immune-mediated liver toxicities includes MMF that targets purine synthesis and thereby limits T cell-mediated anti-liver toxicity (upper left quadrant). Secondary immune suppression in patients with colitis consists of biologics targeting TNF- $\alpha$  (eg, infliximab) or integrins (vedolizumab, upper right quadrant). Secondary immune suppression for lung toxicities of ICI includes MMF and IVIG (lower left quadrant). Treatment of steroid-refractory myocarditis can include MMF, abatacept (fusion protein with CTLA-4 inhibiting CD80/86 interactions), ruxolitinib (JAK 1/2 inhibitor) or ATG (lower right). APC, antigen presenting cell; HLA, human leukocyte antigen; IV, intravenous; MHC, major histocompatibility complex; MMF, mycophenolate mofetil; TCR, T cell receptor.

immune-oncologists and cardiologists experienced with managing irAEs.

## CONCLUSIONS

In this review we have focused on sr-irAEs of liver, colon, lung and heart, as the four most vital organs that can potentially suffer irreversible and life-threatening damage from uncontrolled checkpoint-inhibitor induced autoimmune inflammation (figure 1). Depending on the immunotherapeutic agents, colitis and hepatitis are frequent events, whereas pneumonitis occurs less often and myocarditis is a rare event. Steroid resistance is rare in each of these organs and exact numbers are unknown. International guidelines recommend a rapid step-up of diagnostic and therapeutic measures for each of these organs if steroid treatment does not produce significant improvement after a short time interval of 48–72 hours.<sup>1–3</sup> If not previously carried out, guidelines recommend liver biopsy for steroid-resistant hepatitis, colonoscopy for steroid-resistant colitis, high resolution chest CT and BAL for steroid-resistant pneumonitis and cardiac imaging for steroid-resistant myocarditis. In each case we recommend

consulting with an immune-oncologist and an organ expert experienced with irAE not only to discuss diagnostics and second-line immunosuppression but also to manage steroid taper.

There is no reliable evidence for choosing additional immunosuppression after failure of steroid treatment for any of these organs because no treatment has been prospectively validated. The use of immunosuppressive agents and disease-modifying antirheumatic drugs has been investigated in observational studies in the context of arthritis, providing comparative evidence for the use of interleukin-6 inhibitors, TNF- $\alpha$ -inhibitors and methotrexate.<sup>153 154</sup> However, this kind of comparative evidence is lacking for colitis, hepatitis, pneumonitis and myocarditis. Hence, guideline recommendations remain vague and, in some cases, conflicting. Therefore, we have performed a systematic literature review of available publications about steroid-resistant hepatitis/colitis/pneumonitis/myocarditis, consisting mostly of single-case reports and a few small case series. This review thus has significant limitations, because gathered evidence relies heavily on single case reports or small case series,

thus providing low level evidence. However, currently there is no better evidence and to our knowledge we are providing the first comprehensive compilation of evidence in the case of steroid-resistant hepatitis/colitis/pneumonitis/myocarditis. This shows that there is an urgent need for prospective trials in the setting of steroid-resistant immune-related events, which have become a relevant matter in clinical practise due to the increasing use of checkpoint inhibitors.

Based on the evidence gathered in this review and on our own clinical experience we would recommend using (1) oral MMF for steroid-resistant hepatitis, (2) infliximab for steroid-resistant colitis, followed by vedolizumab if infliximab fails, (3) MMF and IVIG for steroid-resistant pneumonitis, followed by tocilizumab if the first two agents fail, and (4) abatacept or ATG (both with or without MMF) or ruxolitinib with abatacept for steroid-resistant myocarditis. However, treatment decisions should be made on an individual basis, taking into consideration all clinical factors, drug availability, and local experience. In general, we recommend consulting an experienced immune-oncologist and organ expert experienced with irAEs, ideally in the context of a specialized immune-oncology/irAE-board. However, time is of the essence in these often-life-threatening clinical situations and therefore specialist consultations and additional diagnostics should be done immediately in order not to delay necessary treatment decisions (initiation of high-dose steroids and initiation of additional immunosuppression in the case of steroid-resistance).

**Contributors** ED and TW reviewed the literature and drafted the manuscript with inputs from all authors. HL, AZ, DK, LCC and JN have revised the manuscript. All authors approved the final version of the manuscript.

**Funding** The authors have not declared a specific grant for this research from any funding agency in the public, commercial or not-for-profit sectors.

**Competing interests** ED: None. TW: None. DK: Received consulting/advisor fees from AstraZeneca, Amgen, Sanofi, Merck Sharp & Dohme, MSD and support for attending meetings and/or travel from Amgen, Roche, Sanofi. AZ: Received consulting/advisor fees from Bristol-Myers Squibb, Merck Sharp & Dohme, Hoffmann-La Roche, NBE Therapeutics, Secarna, ACM Pharma, and Hookipa, and maintains further non-commercial research agreements with Secarna, Roche, Vectorbiopharma, T3 Pharma and Bright Peak Therapeutics. HL: Received travel grants and consultant fees from BMS, Alektor, and MSD; received research support from BMS, Novartis, GlycoEra and Palleon Pharmaceuticals. JN: Received consulting/advisor fees from AstraZeneca, Bristol-Myers Squibb, Roche/Genentech, Arcus Biosciences, NGM Pharmaceuticals, Bayer, Regeneron, Takeda, Pfizer, Elevation Oncology, AbbVie, Kaleido Biosciences, Daiichi Sankyo. JN: Received research support from AstraZeneca, Bristol-Myers Squibb, Roche/Genentech, Arcus Biosciences and Mirati. LC: Research funding from Bristol-Myers Squibb.

**Patient consent for publication** Not applicable.

**Ethics approval** Not applicable.

**Provenance and peer review** Not commissioned; externally peer reviewed.

**Supplemental material** This content has been supplied by the author(s). It has not been vetted by BMJ Publishing Group Limited (BMJ) and may not have been peer-reviewed. Any opinions or recommendations discussed are solely those of the author(s) and are not endorsed by BMJ. BMJ disclaims all liability and responsibility arising from any reliance placed on the content. Where the content includes any translated material, BMJ does not warrant the accuracy and reliability of the translations (including but not limited to local regulations, clinical guidelines, terminology, drug names and drug dosages), and is not responsible for any error and/or omissions arising from translation and adaptation or otherwise.

**Open access** This is an open access article distributed in accordance with the Creative Commons Attribution Non Commercial (CC BY-NC 4.0) license, which permits others to distribute, remix, adapt, build upon this work non-commercially, and license their derivative works on different terms, provided the original work is properly cited, appropriate credit is given, any changes made indicated, and the use is non-commercial. See <http://creativecommons.org/licenses/by-nc/4.0/>.

## ORCID iDs

Eveline Daetwyler <http://orcid.org/0000-0001-5800-6446>

Till Wallrabenstein <http://orcid.org/0000-0002-6672-3135>

David König <http://orcid.org/0000-0003-3559-6855>

Alfred Zippelius <http://orcid.org/0000-0003-1933-8178>

Heinz Läubli <http://orcid.org/0000-0002-8910-5620>

## REFERENCES

- Haanen J, Obeid M, Spain L, *et al.* Management of toxicities from Immunotherapy: ESMO clinical practice guideline for diagnosis, treatment and follow-up. *Ann Oncol* 2022;33:1217–38.
- SITC Immunotherapy.Pdf [Internet]. n.d. Available: <http://dx.doi.org/jitc-2021-002435>
- Schneider BJ, Naidoo J, Santomaso BD, *et al.* Management of immune-related adverse events in patients treated with immune Checkpoint inhibitor therapy: ASCO guideline update. *JCO* 2021;39:4073–126.
- Postow MA, Sidlow R, Hellmann MD. Immune-related adverse events associated with immune Checkpoint blockade. *N Engl J Med* 2018;378:158–68.
- Michot JM, Bigenwald C, Champiat S, *et al.* Immune-related adverse events with immune Checkpoint blockade: a comprehensive review. *Eur J Cancer* 2016;54:139–48.
- Larkin J, Chiarion-Sileni V, Gonzalez R, *et al.* Five-year survival with combined Nivolumab and Ipilimumab in advanced Melanoma. *N Engl J Med* 2019;381:1535–46.
- Common terminology criteria for adverse events (CTCAE). n.d. Available: [https://ctep.cancer.gov/protocoldevelopment/electronic\\_applications/docs/CTCAE\\_v5\\_Quick\\_Reference\\_8.5x11.pdf](https://ctep.cancer.gov/protocoldevelopment/electronic_applications/docs/CTCAE_v5_Quick_Reference_8.5x11.pdf)
- Xu C, Chen Y-P, Du X-J, *et al.* Comparative safety of immune Checkpoint inhibitors in cancer: systematic review and network meta-analysis. *BMJ* 2018;363:k4226.
- Naidoo J, Murphy C, Atkins MB, *et al.* Society for Immunotherapy of cancer (SITC) consensus definitions for immune Checkpoint inhibitor-associated immune-related adverse events (irAEs) terminology. *J Immunother Cancer* 2023;11:e006398.
- Naidoo J, Wang X, Woo KM, *et al.* Pneumonitis in patients treated with anti-programmed Death-1/programmed death ligand 1 therapy. *J Clin Oncol* 2017;35:709–17.
- Dougan M, Wang Y, Rubio-Tapia A, *et al.* AGA clinical practice update on diagnosis and management of immune Checkpoint inhibitor colitis and hepatitis: expert review. *Gastroenterology* 2021;160:1384–93.
- Huffman BM, Kottschade LA, Kamath PS, *et al.* Hepatotoxicity after immune Checkpoint inhibitor therapy in Melanoma: natural progression and management. *Am J Clin Oncol* 2018;41:760–5.
- Suzman DL, Pelosof L, Rosenberg A, *et al.* Hepatotoxicity of immune Checkpoint inhibitors: an evolving picture of risk associated with a vital class of Immunotherapy agents. *Liver Int* 2018;38:976–87.
- Martins F, Sofiya L, Sykietis GP, *et al.* Adverse effects of immune-Checkpoint inhibitors: epidemiology, management and surveillance. *Nat Rev Clin Oncol* 2019;16:563–80.
- Eggermont AMM, Robert C, Suciu S. Adjuvant Pembrolizumab in Resected stage III Melanoma. *N Engl J Med* 2018;379:593–5.
- Horvat TZ, Adel NG, Dang T-O, *et al.* Immune-related adverse events, need for systemic immunosuppression, and effects on survival and time to treatment failure in patients with Melanoma treated with Ipilimumab at Memorial Sloan Kettering cancer center. *J Clin Oncol* 2015;33:3193–8.
- Weber J, Mandala M, Del Vecchio M, *et al.* Adjuvant Nivolumab versus Ipilimumab in Resected stage III or IV Melanoma. *N Engl J Med* 2017;377:1824–35.
- Hodi FS, O'Day SJ, McDermott DF, *et al.* Improved survival with Ipilimumab in patients with metastatic Melanoma. *N Engl J Med* 2010;363:711–23.
- Weber JS, O'Day S, Urban W, *et al.* Phase I/II study of Ipilimumab for patients with metastatic Melanoma. *J Clin Oncol* 2008;26:5950–6.
- Cheung V, Gupta T, Payne M, *et al.* Immunotherapy-related hepatitis: real-world experience from a tertiary centre. *Frontline Gastroenterol* 2019;10:364–71.



- 21 Patrinely JR, McGuigan B, Chandra S, et al. A multicenter characterization of hepatitis associated with immune Checkpoint inhibitors. *Oncol Immunology* 2021;10.
- 22 Ziogas DC, Gkoufa A, Cholongitas E, et al. When steroids are not enough in immune-related hepatitis: Current clinical challenges discussed on the basis of a case report. *J Immunother Cancer* 2020;8:e001322.
- 23 Doherty GJ, Duckworth AM, Davies SE, et al. Severe steroid-resistant anti-Pd1 T-cell Checkpoint inhibitor-induced hepatotoxicity driven by biliary injury. *ESMO Open* 2017;2:e000268.
- 24 Iwamoto K, Ishitsuka Y, Tanaka R, et al. Azathioprine combination therapy for steroid-refractory hepatic immune system-related adverse events. *Eur J Dermatol* 2017;27:301–3.
- 25 Johncilla M, Misdraji J, Pratt DS, et al. Ipilimumab-associated hepatitis: Clinicopathologic characterization in a series of 11 cases. *Am J Surg Pathol* 2015;39:1075–84.
- 26 Luo J, Beattie JA, Fuentes P, et al. Beyond steroids: immunosuppressants in steroid-refractory or resistant immune-related adverse events. *J Thorac Oncol* 2021;16:1759–64.
- 27 Corrigan R, Haydon G, Thompson F, et al. Infliximab for the treatment of refractory immune-related hepatitis secondary to Checkpoint inhibitors: A case report. *JHEP Rep* 2019;1:66–9.
- 28 Chmiel KD, Suan D, Liddle C, et al. Resolution of severe Ipilimumab-induced hepatitis after Antithymocyte globulin therapy. *J Clin Oncol* 2011;29:e237–40.
- 29 Ahmed T, Pandey R, Shah B, et al. Resolution of Ipilimumab induced severe hepatotoxicity with triple immunosuppressants therapy [BMJ Case Rep [Internet]. *BMJ Case Rep* 2015;2015:bcr2014208102.
- 30 Spänkuch I, Gassenmaier M, Tampouri I, et al. "Corrigendum to "severe hepatitis under combined Immunotherapy: resolution under corticosteroids plus anti-Thymocyte Immunoglobulins" [Eur J cancer 81 (August 2017) 203–205]". *Eur J Cancer* 2017;87:221.
- 31 Tanaka R, Fujisawa Y, Sae I, et al. Severe hepatitis arising from Ipilimumab administration, following Melanoma treatment with Nivolumab. *Jpn J Clin Oncol* 2017;47:175–8.
- 32 McGuire HM, Shklovskaya E, Edwards J, et al. Anti-PD-1-induced high-grade hepatitis associated with corticosteroid-resistant T cells: a case report. *Cancer Immunol Immunother* 2018;67:563–73.
- 33 Nakano K, Nishizawa M, Fukuda N, et al. Mycophenolate mofetil as a successful treatment of corticosteroid-resistant immune Checkpoint inhibitor-induced hepatitis. *Oxf Med Case Reports* 2020;2020:omaa027.
- 34 Onishi S, Tajika M, Bando H, et al. Ursodeoxycholic acid and Bezafibrate were useful for steroid-refractory, immune-related hepatitis: a case report. *J Med Case Rep* 2020;14:230.
- 35 Miller ED, Abu-Sbeih H, Styckel B, et al. Clinical characteristics and adverse impact of hepatotoxicity due to immune Checkpoint inhibitors. *Am J Gastroenterol* 2020;115:251–61.
- 36 Romanski NA, Holmstroem RB, Ellebaek E, et al. Characterization of risk factors and efficacy of medical management of immune-related hepatotoxicity in real-world patients with metastatic Melanoma treated with immune Checkpoint inhibitors. *Eur J Cancer* 2020;130:211–8.
- 37 Ruini C, Haas C, Mastnik S, et al. Primary biliary cirrhosis and granulomatous hepatitis after immune Checkpoint blockade in patients with metastatic Melanoma: report of 2 cases and literature discussion. *J Immunother* 2021;44:71–5.
- 38 Au M, Body A, Mant A, et al. Checkpoint inhibitor induced steroid refractory drug-induced liver injury. *Intern Med J* 2021;51:810–1.
- 39 Ueno M, Takabatake H, Hata A, et al. Mycophenolate mofetil for immune Checkpoint inhibitor-related hepatotoxicity relapsing during dose reduction of corticosteroid: A report of two cases and literature review. *Cancer Rep (Hoboken)* 2022;5:e1624.
- 40 Thompson JA, Schneider BJ, Brahmer J, et al. NCCN guidelines insights: management of Immunotherapy-related toxicities, version 1.2020. *J Natl Compr Canc Netw* 2020;18:230–41.
- 41 Zhang HC, Luo W, Wang Y. Acute liver injury in the context of immune Checkpoint inhibitor-related colitis treated with Infliximab. *J Immunotherapy Cancer* 2019;7.
- 42 Hagiwara S, Watanabe T, Kudo M, et al. Clinicopathological analysis of hepatic immune-related adverse events in comparison with autoimmune hepatitis and graft-versus host disease. *Sci Rep* 2021;11:9242.
- 43 Maas-Bauer K, Kiote-Schmidt C, Bertz H, et al. Ruxolitinib-ECP combination treatment for refractory severe chronic graft-versus-host disease. *Bone Marrow Transplant* 2021;56:909–16.
- 44 Zeiser R, Burchert A, Lengerke C, et al. Ruxolitinib in corticosteroid-refractory graft-versus-host disease after allogeneic stem cell transplantation: a multicenter survey. *Leukemia* 2015;29:2062–8.
- 45 Greinix HT, Worel N, Just U, et al. Extracorporeal Photopheresis in acute and chronic graft-versus-host disease. *Transfus Apher Sci* 2014;50:349–57.
- 46 Prieux-Klotz C, Dior M, Damotte D, et al. Immune Checkpoint inhibitor-induced colitis. *Diagnosis and Management Target Oncol* 2017.
- 47 Eggermont AMM, Chiarion-Sileni V, Grob J-J, et al. Prolonged survival in stage III Melanoma with Ipilimumab adjuvant therapy. *N Engl J Med* 2016;375:1845–55.
- 48 Som A, Mandaliya R, Alsaadi D, et al. Immune Checkpoint inhibitor-induced colitis: A comprehensive review. *World J Clin Cases* 2019;7:405–18.
- 49 Gong Z, Wang Y. Immune Checkpoint inhibitor-mediated diarrhea and colitis: A clinical review. *JCO Oncol Pract* 2020;16:453–61.
- 50 Larkin J, Chiarion-Sileni V, Gonzalez R, et al. Combined Nivolumab and Ipilimumab or monotherapy in untreated Melanoma. *N Engl J Med* 2015;373:23–34.
- 51 Robert C, Schachter J, Long GV, et al. Pembrolizumab versus Ipilimumab in advanced Melanoma. *N Engl J Med* 2015;372:2521–32.
- 52 Weber JS, Kähler KC, Hauschild A. Management of immune-related adverse events and Kinetics of response with Ipilimumab. *J Clin Oncol* 2012;30:2691–7.
- 53 Geukes Foppen MH, Rozeman EA, van Wilpe S, et al. Immune Checkpoint inhibition-related colitis: symptoms, endoscopic features, Histology and response to management. *ESMO Open* 2018;3:e000278.
- 54 Burla J, Bluemel S, Biedermann L, et al. Retrospective analysis of treatment and complications of immune Checkpoint inhibitor-associated colitis: histological ulcerations as potential Predictor for a steroid-refractory disease course. *Inflamm Intest Dis* 2020;5:109–16.
- 55 Wang Y, Abu-Sbeih H, Mao E, et al. Endoscopic and histologic features of immune Checkpoint inhibitor-related colitis. *Inflamm Bowel Dis* 2018;24:1695–705.
- 56 Jain A, Lipson EJ, Sharfman WH, et al. Colonic ulcerations may predict steroid-refractory course in patients with Ipilimumab-mediated Enterocolitis. *WJG* 2017;23:2023.
- 57 Schroeder KW, Tremaine WJ, Ilstrup DM. Coated oral 5-Aminosalicylic acid therapy for mildly to moderately active ulcerative colitis. A randomized study. *N Engl J Med* 1987;317:1625–9.
- 58 Mooradian MJ, Wang DY, Coromilas A, et al. Mucosal inflammation predicts response to systemic steroids in immune Checkpoint inhibitor colitis. *J Immunother Cancer* 2020;8:e000451.
- 59 Pagès C, Gornet JM, Monsel G, et al. Ipilimumab-induced acute severe colitis treated by Infliximab. *Melanoma Res* 2013;23:227–30.
- 60 Hsieh A-C, Ferman M, Brown MP, et al. Vedolizumab: a novel treatment for Ipilimumab-induced colitis [BMJ Case Rep [Internet]. *BMJ Case Rep* 2016;2016:bcr2016216641.
- 61 Iyoda T, Kurita N, Takada A, et al. Resolution of Infliximab-refractory Nivolumab-induced acute severe Enterocolitis after cyclosporine treatment in a patient with non-small cell lung cancer. *Am J Case Rep* 2018;19:360–4.
- 62 Esfahani K, Hudson M, Batist G. Tofacitinib for refractory immune-related colitis from PD-1 therapy. *N Engl J Med* 2020;382:2374–5.
- 63 Cheng R, Cooper A, Kench J, et al. Ipilimumab-induced toxicities and the Gastroenterologist. *J Gastroenterol Hepatol* 2015;30:657–66.
- 64 Nassri AB, Muenyi V, Alkhasawneh A, et al. Ipilimumab and Nivolumab induced steroid-refractory colitis treated with Infliximab: A case report. *World J Gastrointest Pharmacol Ther* 2019;10:29–34.
- 65 Connolly EA, Walker T, Van der Westhuizen A. Impending Infliximab access crisis: a case of steroid-refractory, relapsing Immunotherapy-induced colitis responsive to Infliximab. *Intern Med J* 2020;50:767–8.
- 66 Klemm N, Trasolini R, Chahal D, et al. Vedolizumab for steroid & Infliximab refractory immune Checkpoint inhibitor associated colitis. *Clin Res Hepatol Gastroenterol* 2021;45:101604.
- 67 Perez Del Nogal G, Patel N. Refractory Checkpoint inhibitor colitis responsive to Ustekinumab. *ACG Case Rep J* 2022;9:e00946.
- 68 Zellweger M, Rogler G, Komminoth P, et al. Management of persistent colitis after successful Immunotherapy for non-small cell carcinoma of the lung. *Z Gastroenterol* 2022;60:1124–30.
- 69 Apostolova P, Unger S, von Bubnoff D, et al. Extracorporeal Photopheresis for colitis induced by Checkpoint-inhibitor therapy. *N Engl J Med* 2020;382:294–6.
- 70 Sasson SC, Slevin SM, Cheung VTF, et al. Interferon-gamma-producing CD8<sup>+</sup> tissue resident memory T cells are a Targetable hallmark of immune Checkpoint inhibitor-colitis. *Gastroenterology* 2021;161:1229–44.

- 71 Verschuren EC, van den Eertwegh AJ, Wonders J, *et al.* Clinical, endoscopic, and histologic characteristics of Ipilimumab-associated colitis. *Clin Gastroenterol Hepatol* 2016;14:836–42.
- 72 Johnston RL, Lutzky J, Chodhry A, *et al.* Cytotoxic T-lymphocyte-associated antigen 4 antibody-induced colitis and its management with Infliximab. *Dig Dis Sci* 2009;54:2538–40.
- 73 Marthey L, Mateus C, Mussini C, *et al.* Cancer Immunotherapy with anti-CTLA-4 Monoclonal antibodies induces an inflammatory bowel disease. *ECCOJC* 2016;10:395–401.
- 74 Beck KE, Blansfield JA, Tran KQ, *et al.* Enterocolitis in patients with cancer after antibody blockade of cytotoxic T-lymphocyte-associated antigen 4. *JCO* 2006;24:2283–9.
- 75 Bergqvist V, Hertvig E, Gedeon P, *et al.* Vedolizumab treatment for immune Checkpoint inhibitor-induced Enterocolitis. *Cancer Immunol Immunother* 2017;66:581–92.
- 76 Abu-Sbeih H, Ali FS, Wang Y. Clinical review on the utility of fecal microbiota transplantation in immunocompromised patients. *Curr Gastroenterol Rep* 2019;21.
- 77 Abu-Sbeih H, Ali FS, Alsaadi D, *et al.* Outcomes of Vedolizumab therapy in patients with immune Checkpoint inhibitor-induced colitis: a multi-center study. *J Immunother Cancer* 2018;6:142.
- 78 Lord JD, Hackman RC, Moklebust A, *et al.* Refractory colitis following anti-Ctla4 antibody therapy: analysis of Mucosal Foxp3+ T cells. *Dig Dis Sci* 2010;55:1396–405.
- 79 Zhang E, Kiely C, Sandanayake N, *et al.* Calcineurin inhibitors in steroid and anti-TNF-alpha refractory immune Checkpoint inhibitor colitis. *JGH Open* 2021;5:558–62.
- 80 Thomas AS, Ma W, Wang Y. Ustekinumab for refractory colitis associated with immune Checkpoint inhibitors. *N Engl J Med* 2021;384:581–3.
- 81 Wang Y, Wiesnoski DH, Helmink BA, *et al.* Fecal Microbiota transplantation for refractory immune Checkpoint inhibitor-associated colitis. *Nat Med* 2018;24:1804–8.
- 82 Dahl EK, Abed OK, Kjeldsen J, *et al.* Safety and efficacy of Infliximab and corticosteroid therapy in Checkpoint inhibitor-induced colitis. *Aliment Pharmacol Ther* 2023;57:152–3.
- 83 Bishu S, Melia J, Sharfman W, *et al.* Efficacy and outcome of tofacitinib in immune Checkpoint inhibitor colitis. *Gastroenterology* 2021;160:932–4.
- 84 Abu-Sbeih H, Ali FS, Wang X, *et al.* Early introduction of selective immunosuppressive therapy associated with favorable clinical outcomes in patients with immune Checkpoint inhibitor-induced colitis. *J Immunotherapy Cancer* 2019;7.
- 85 Badran YR, Cohen JV, Brastianos PK, *et al.* Concurrent therapy with immune Checkpoint inhibitors and TNF $\alpha$  blockade in patients with gastrointestinal immune-related adverse events. *J Immunother Cancer* 2019;7:226.
- 86 Abu-Sbeih H, Tang T, Faleck DM, *et al.* Outcomes of immune Checkpoint inhibitor-mediated colitis: multicenter cohort study. *JCO* 2021;39:2643.
- 87 Westdorp H, Sweep MWD, Gorris MAJ, *et al.* Mechanisms of immune Checkpoint inhibitor-mediated colitis. *Front Immunol* 2021;12:768957.
- 88 Luoma AM, Suo S, Williams HL, *et al.* Molecular pathways of colon inflammation induced by cancer Immunotherapy. *Cell* 2020;182:655–71.
- 89 Orfanoudaki E, Foteiniogiannopoulou K, Theodoraki E, *et al.* Recent advances in the optimization of anti-TNF treatment in patients with inflammatory bowel disease. *J Clin Med* 2023;12:2452.
- 90 Guo Y, Lu N, Bai A. Clinical use and mechanisms of Infliximab treatment on inflammatory bowel disease: a recent update. *Biomed Res Int* 2013;2013:581631.
- 91 Danylesko I, Bukauskas A, Paulson M, *et al.* Anti-A4B7 integrin Monoclonal antibody (Vedolizumab) for the treatment of steroid-resistant severe intestinal acute graft-versus-host disease. *Bone Marrow Transplant* 2019;54:987–93.
- 92 Wyant T, Fedyk E, Abhyankar B. An overview of the mechanism of action of the Monoclonal antibody Vedolizumab. *J Crohns Colitis* 2016;10:1437–44.
- 93 Voth E, Khanna S. Fecal Microbiota transplantation for treatment of patients with recurrent Clostridioides difficile infection. *Expert Rev Anti Infect Ther* 2020;18:669–76.
- 94 Choi HH, Cho Y-S. Fecal Microbiota transplantation: Current applications, effectiveness, and future perspectives. *Clin Endosc* 2016;49:257–65.
- 95 Youngster I, Sauk J, Pindar C, *et al.* Fecal Microbiota transplant for relapsing Clostridium difficile infection using a frozen Inoculum from unrelated donors: a randomized, open-label, controlled pilot study. *Clin Infect Dis* 2014;58:1515–22.
- 96 Gough E, Shaikh H, Manges AR. Systematic review of intestinal Microbiota transplantation (fecal Bacteriotherapy) for recurrent Clostridium difficile infection. *Clin Infect Dis* 2011;53:994–1002.
- 97 van Nood E, Dijkgraaf MGW, Keller JJ. Duodenal infusion of Feces for recurrent Clostridium difficile. *N Engl J Med* 2013;368:2145.
- 98 Bennet JD, Brinkman M. Treatment of ulcerative colitis by implantation of normal Colonic Flora. *Lancet* 1989;1:164.
- 99 Colman RJ, Rubin DT. Fecal Microbiota transplantation as therapy for inflammatory bowel disease: a systematic review and meta-analysis. *J Crohns Colitis* 2014;8:1569–81.
- 100 Moayyedi P, Surette MG, Kim PT, *et al.* Fecal Microbiota transplantation induces remission in patients with active ulcerative colitis in a randomized controlled trial. *Gastroenterology* 2015;149:102–9.
- 101 Rossen NG, Fuentes S, van der Spek MJ, *et al.* Findings from a randomized controlled trial of fecal transplantation for patients with ulcerative colitis. *Gastroenterology* 2015;149:110–8.
- 102 Nakanishi Y, Masuda T, Yamaguchi K, *et al.* Pre-existing interstitial lung abnormalities are risk factors for immune Checkpoint inhibitor-induced interstitial lung disease in non-small cell lung cancer. *Respir Investig* 2019;57:451–9.
- 103 Pillai RN, Behera M, Owonikoko TK, *et al.* Comparison of the toxicity profile of PD-1 versus PD-L1 inhibitors in non-small cell lung cancer: A systematic analysis of the literature. *Cancer* 2018;124:271–7.
- 104 Tiu BC, Zubiri L, Iheke J, *et al.* Real-world incidence and impact of Pneumonitis in patients with lung cancer treated with immune Checkpoint inhibitors: a multi-institutional cohort study. *J Immunother Cancer* 2022;10:e004670.
- 105 Delaunay M, Cadranet J, Lusque A, *et al.* Immune-Checkpoint inhibitors associated with interstitial lung disease in cancer patients. *Eur Respir J* 2017;50:1700050.
- 106 Balaji A, Hsu M, Lin CT, *et al.* Steroid-refractory PD-(L)1 Pneumonitis: incidence, clinical features, treatment, and outcomes. *J Immunother Cancer* 2021;9:e001731.
- 107 Nishino M, Giobbie-Hurder A, Hatabu H, *et al.* Incidence of programmed cell death 1 inhibitor-related Pneumonitis in patients with advanced cancer: A systematic review and meta-analysis. *JAMA Oncol* 2016;2:1607–16.
- 108 Asher N, Marom EM, Ben-Betzalel G, *et al.* Recurrent Pneumonitis in patients with Melanoma treated with immune Checkpoint inhibitors. *Oncologist* 2019;24:640–7.
- 109 Naidoo J, Cottrell TR, Lipson EJ, *et al.* Chronic immune Checkpoint inhibitor Pneumonitis. *J Immunother Cancer* 2020;8:e000840.
- 110 Camard M, Besse B, Cariou P-L, *et al.* Prevalence and outcome of steroid-resistant/refractory Pneumonitis induced by immune Checkpoint inhibitors. *Respiratory Medicine and Research* 2022;82:100969.
- 111 Beattie J, Rizvi H, Fuentes P, *et al.* Success and failure of additional immune Modulators in steroid-refractory/resistant Pneumonitis related to immune Checkpoint blockade. *J Immunother Cancer* 2021;9:e001884.
- 112 Petri CR, Patell R, Batalini F, *et al.* Severe pulmonary toxicity from immune checkpoint inhibitor treated successfully with intravenous immunoglobulin: case report and review of the literature. *Respir Med Case Rep* 2019;27:100834.
- 113 Stroud CR, Hegde A, Cherry C, *et al.* Tocilizumab for the management of immune mediated adverse events secondary to PD-1 blockade. *J Oncol Pharm Pract* 2019;25:551–7.
- 114 Cooksley T, Marshall W, Gupta A. Early Infliximab in life-threatening immune-mediated Pneumonitis. *QJM* 2019;112:929–30.
- 115 Sawai Y, Katsuya Y, Shinozaki-Ushiku A, *et al.* Rapid temporal improvement of Pembrolizumab-induced Pneumonitis using the anti-TNF-A antibody Infliximab. *Drug Discov Ther* 2019;13:164–7.
- 116 Andruska N, Mahapatra L, Hebbard C, *et al.* Severe Pneumonitis refractory to steroids following anti-PD-1 Immunotherapy. *BMJ Case Rep* 2018:bcr2018225937.
- 117 Chen Z, He J. Infliximab in the treatment of Tislelizumab-induced steroid-refractory immune Checkpoint inhibitor-related pneumonia: case report and literature review. *Transl Cancer Res* 2022;11:3309–14.
- 118 Huang S, Jordan A, Jenneman D, *et al.* Rapid improvement following receipt of Infliximab in steroid-refractory Durvalumab-associated grade 3 Pneumonitis. *Cureus* 2022;14:e22295.
- 119 Ortega Sanchez G, Jahn K, Savic S, *et al.* Treatment of mycophenolate-resistant immune-related organizing pneumonia with Infliximab. *J Immunother Cancer* 2018;6:85.
- 120 Utsumi H, Araya J, Okuda K, *et al.* Successful treatment of steroid-refractory immune Checkpoint inhibitor-related Pneumonitis with triple combination therapy: a case report. *Cancer Immunol Immunother* 2020;69:2033–9.

- 121 Xie X-H, Deng H-Y, Lin X-Q, *et al.* Case report: Nintedanib for Pembrolizumab-related Pneumonitis in a patient with non-small cell lung cancer. *Front Oncol* 2021;11:673877.
- 122 Läubli H, Koelzer VH, Matter MS, *et al.* The T cell repertoire in tumors overlaps with pulmonary inflammatory lesions in patients treated with Checkpoint inhibitors. *Oncoimmunology* 2018;7:e1386362.
- 123 Ando H, Suzuki K, Yanagihara T. Insights into potential pathogenesis and treatment options for immune-Checkpoint inhibitor-related Pneumonitis. *Biomedicines* 2021;9:1484.
- 124 Suresh K, Naidoo J, Zhong Q, *et al.* The alveolar immune cell landscape is Dysregulated in Checkpoint inhibitor Pneumonitis. *J Clin Invest* 2019;129:4305–15.
- 125 Tahir SA, Gao J, Miura Y, *et al.* Autoimmune antibodies correlate with immune Checkpoint therapy-induced toxicities. *Proc Natl Acad Sci U S A* 2019;116:22246–51.
- 126 Mahmood SS, Fradley MG, Cohen JV, *et al.* Myocarditis in patients treated with immune Checkpoint inhibitors. *J Am Coll Cardiol* 2018;71:1755–64.
- 127 Salem J-E, Manouchehri A, Moey M, *et al.* Cardiovascular toxicities associated with immune Checkpoint inhibitors: an observational, retrospective, Pharmacovigilance study. *Lancet Oncol* 2018;19:1579–89.
- 128 Moslehi JJ, Salem J-E, Sosman JA, *et al.* Increased reporting of fatal immune Checkpoint inhibitor-associated myocarditis. *Lancet* 2018;391.
- 129 Bonaca MP, Olenchick BA, Salem J-E, *et al.* Myocarditis in the setting of cancer Therapeutics: proposed case definitions for emerging clinical syndromes in Cardio-oncology. *Circulation* 2019;140:80–91.
- 130 Herrmann J, Lenihan D, Armenian S, *et al.* Defining cardiovascular toxicities of cancer therapies: an international Cardio-oncology society (IC-OS) consensus statement. *Eur Heart J* 2022;43:280–99.
- 131 Johnson DB, Balko JM, Compton ML, *et al.* Fulminant myocarditis with combination immune Checkpoint blockade. *N Engl J Med* 2016;375:1749–55.
- 132 Lyon AR, López-Fernández T, Couch LS, *et al.* ESC guidelines on Cardio-oncology developed in collaboration with the European hematology Association (EHA), the European society for therapeutic Radiology and oncology (ESTRO) and the International Cardio-oncology society (IC-OS). *Eur Heart J Cardiovasc Imaging* 2022;23:e333–465.
- 133 Cautela J, Zerrouh S, Gaubert M, *et al.* Intensified immunosuppressive therapy in patients with immune Checkpoint inhibitor-induced myocarditis. *J Immunother Cancer* 2020;8:e001887.
- 134 Salem J-E, Allenbach Y, Vozy A, *et al.* Abatacept for severe immune Checkpoint inhibitor-associated myocarditis. *N Engl J Med* 2019;380:2377–9.
- 135 Jespersen MS, Fanø S, Stenør C, *et al.* A case report of immune Checkpoint inhibitor-related steroid-refractory myocarditis and myasthenia gravis-like Myositis treated with Abatacept and mycophenolate mofetil. *European Heart Journal - Case Reports* 2021;5.
- 136 Kalapurackal Mathai V, Black A, Lovibond S, *et al.* Use of Abatacept in steroid refractory, immune Checkpoint-induced myocarditis. *Intern Med J* 2021;51:1971–2.
- 137 Esfahani K, Buhlaiga N, Thébault P, *et al.* Alemtuzumab for immune-related myocarditis due to PD-1 therapy. *N Engl J Med* 2019;380:2375–6.
- 138 Saibil SD, Bonilla L, Majeed H, *et al.* Fatal myocarditis and Rhabdomyositis in a patient with stage IV Melanoma treated with combined Ipilimumab and Nivolumab. *Current Oncology* 2019;26:418–21.
- 139 Arangalage D, Delyon J, Lermuzeaux M, *et al.* Survival after fulminant myocarditis induced by immune-Checkpoint inhibitors. *Ann Intern Med* 2017;167:683.
- 140 Compton F, He L, Sarode R, *et al.* Immune Checkpoint inhibitor toxicity: A new indication for therapeutic plasma exchange *J of Clinical Apheresis* 2021;36:645–8. 10.1002/jca.21890 Available: <https://onlinelibrary.wiley.com/toc/10981101/36/4>
- 141 Schiopu SRI, Käsmann L, Schönermarck U, *et al.* Pembrolizumab-induced myocarditis in a patient with malignant Mesothelioma: plasma exchange as a successful emerging therapy-case report. *Transl Lung Cancer Res* 2021;10:1039–46.
- 142 Tay RY, Blackley E, McLean C, *et al.* Successful use of equine anti-Thymocyte globulin (ATGAM) for fulminant myocarditis secondary to Nivolumab therapy. *Br J Cancer* 2017;117:921–4.
- 143 Jain V, Mohebtash M, Rodrigo ME, *et al.* Autoimmune myocarditis caused by immune Checkpoint inhibitors treated with Antithymocyte globulin. *J Immunother* 2018;41:332–5.
- 144 Bacig NV, Ngo C, Yeh AC, *et al.* Steroid-refractory autoimmune myocarditis after Pembrolizumab therapy: failure of equine anti-Thymocyte globulin to prevent heart failure. *J Clin Case Rep* 2019;2:1–4.
- 145 Xing Q, Zhang Z, Zhu B, *et al.* Case report: treatment for steroid-refractory immune-related myocarditis with tofacitinib. *Front Immunol* 2022;13:944013.
- 146 Doms J, Prior JO, Peters S, *et al.* Tocilizumab for refractory severe immune Checkpoint inhibitor-associated myocarditis. *Ann Oncol* 2020;31:1273–5.
- 147 Zhang RS, Padegimas A, Murphy KM, *et al.* Treatment of corticosteroid refractory immune Checkpoint inhibitor myocarditis with Infliximab: a case series. *Cardiooncology* 2021;7:13.
- 148 Wang C, Lin J, Wang Y, *et al.* Case series of steroid-resistant immune Checkpoint inhibitor associated myocarditis: A comparative analysis of corticosteroid and tofacitinib treatment. *Front Pharmacol* 2021;12:770631.
- 149 Salem J-E, Bretagne M, Abbar B, *et al.* Abatacept/Ruxolitinib and screening for concomitant respiratory muscle failure to mitigate fatality of immune-Checkpoint inhibitor myocarditis. *Cancer Discov* 2023;13:1100–15.
- 150 Ji C, Roy MD, Golas J, *et al.* Myocarditis in cynomolgus monkeys following treatment with immune Checkpoint inhibitors. *Clin Cancer Res* 2019;25:4735–48.
- 151 Heine A, Held SAE, Daecke SN, *et al.* The JAK-inhibitor Ruxolitinib impairs Dendritic cell function in vitro and in vivo. *Blood* 2013;122:1192–202.
- 152 Albeituni S, Verbist KC, Tedrick PE, *et al.* Mechanisms of action of Ruxolitinib in murine models of Hemophagocytic Lymphohistiocytosis. *Blood* 2019;134:147–59.
- 153 Braaten TJ, Brahmer JR, Forde PM, *et al.* Immune Checkpoint inhibitor-induced inflammatory arthritis persists after Immunotherapy cessation. *Ann Rheum Dis* 2020;79:332–8.
- 154 Bass AR, Abdel-Wahab N, Reid PD, *et al.* Comparative safety and effectiveness of TNF inhibitors, IL6 inhibitors and methotrexate for the treatment of immune Checkpoint inhibitor-associated arthritis. *Ann Rheum Dis* 2023;82:920–6. 10.1136/ard-2023-223885 Available: <http://dx.doi.org/10.1136/ard-2023-223885>